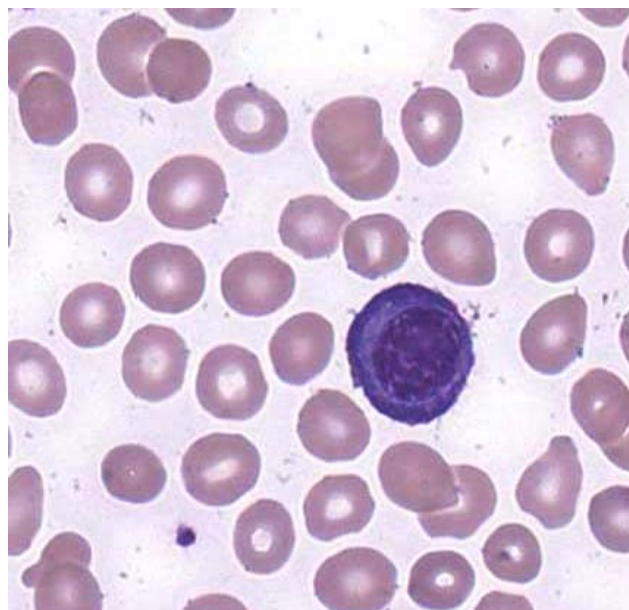
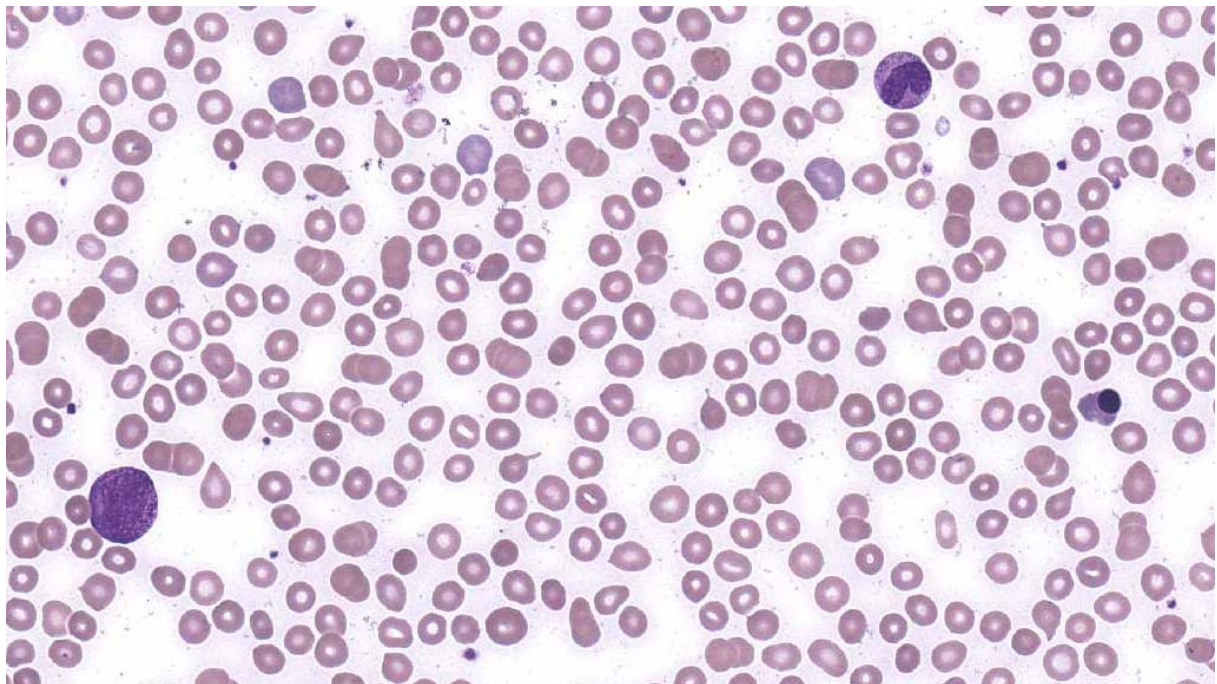




**INTERIM REPORT: MORPHOLOGY PROGRAM  
CASE STUDY MO8-10c DIAGNOSIS:**

**Plasma cell myeloma**

32 year old male. Bone pain and fatigue: WCC =  $13.8 \times 10^9/L$  RCC =  $3.19 \times 10^{12}/L$   
Hb = 94 g/L MCV = 87.4 pg MCH = 29.6 pg MCHC = 339 g/L PLT =  $77 \times 10^9/L$



Discussion and other diagnostic interpretations that have been considered acceptable, by the Morphology Committee, will be listed in your final report.