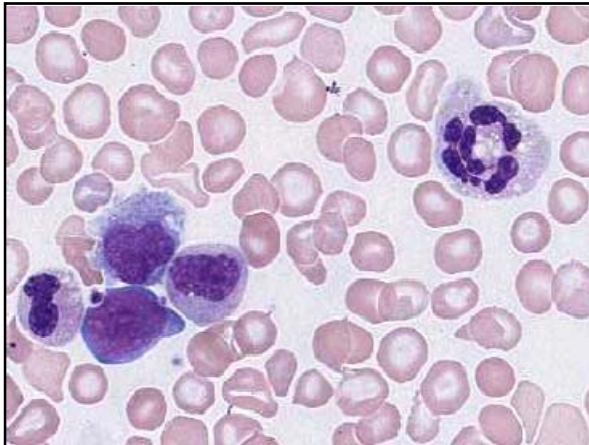
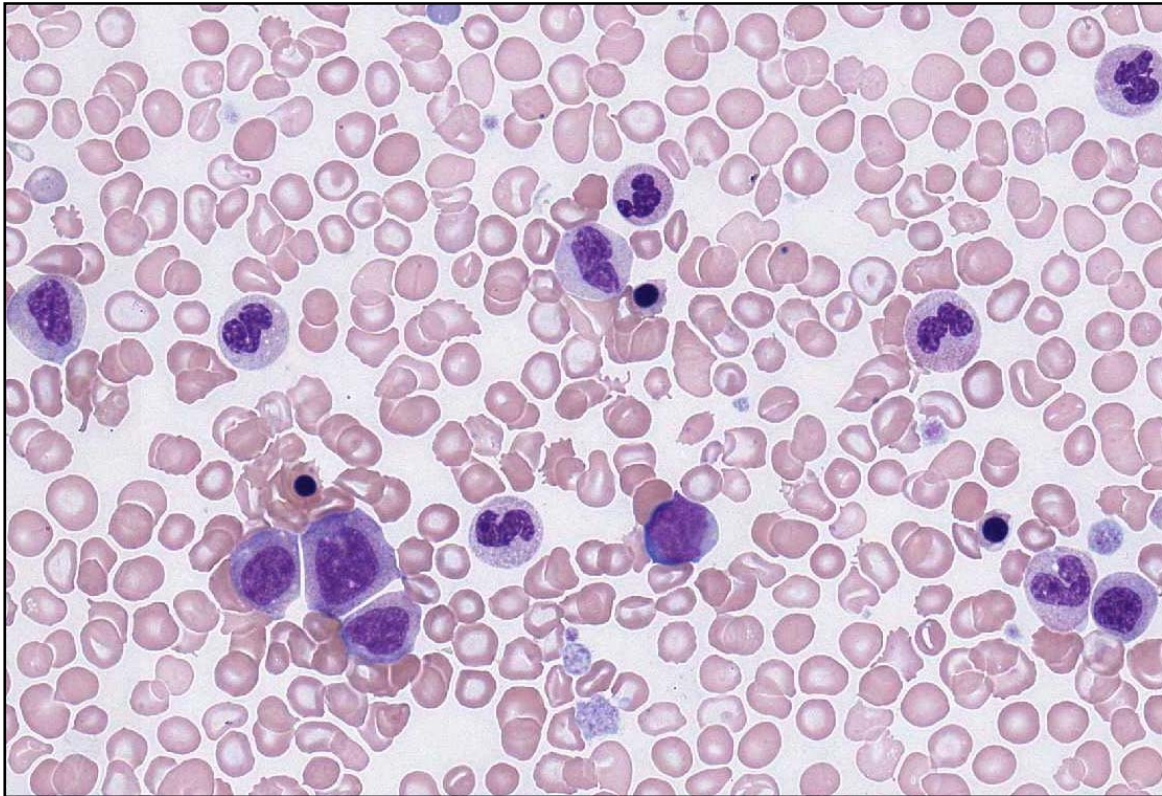




**INTERIM REPORT: MORPHOLOGY PROGRAM
CASE STUDY MO9-07c DIAGNOSIS:**

Myeloproliferative Disorder in transformation

Illustrated below are photographs taken from Slide MO9-07c to demonstrate the morphological features in case study 3.



Discussion and other diagnostic interpretations that have been considered acceptable, by the Morphology Committee, will be listed in your final report.