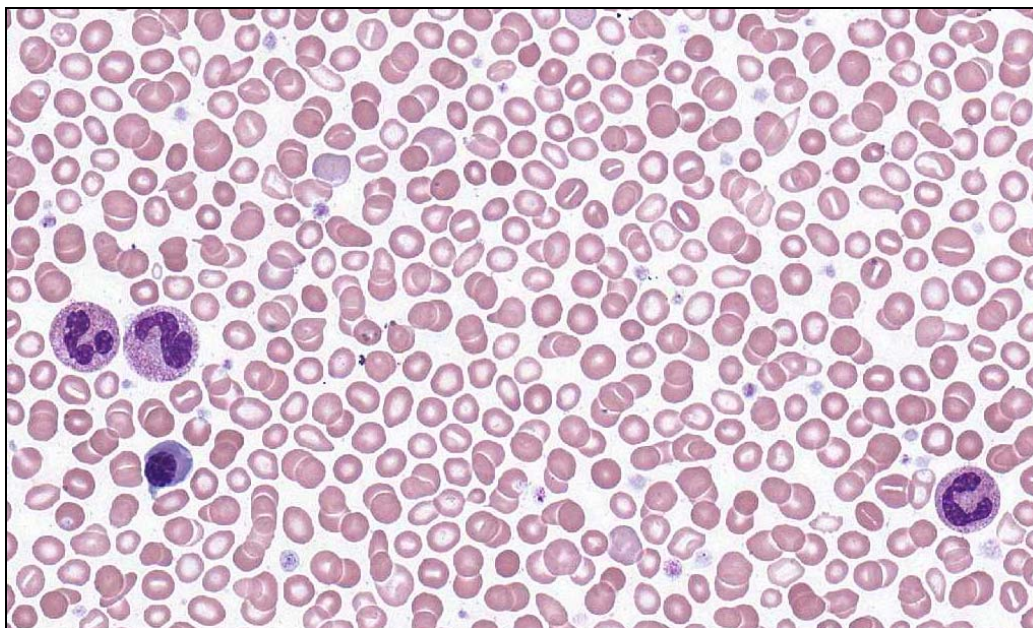
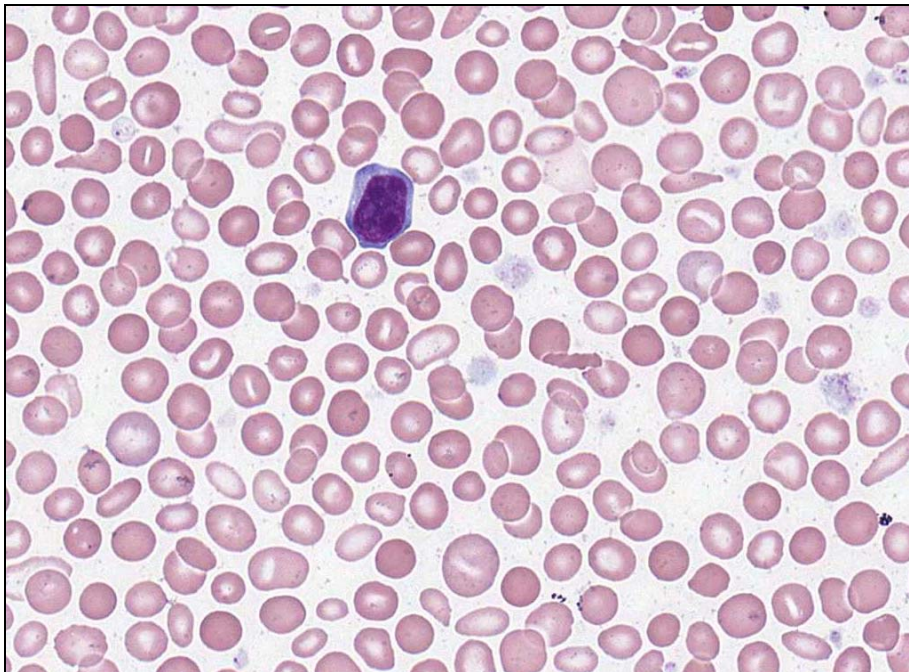




**INTERIM REPORT: MORPHOLOGY PROGRAM
CASE STUDY MO9-10b DIAGNOSIS:
Polycythaemia vera with secondary iron deficiency**

Illustrated below are photographs taken from Slide MO9-10b to demonstrate the morphological features in case study 2.



Discussion and other diagnostic interpretations that have been considered acceptable, by the Morphology Committee, will be listed in your final report.