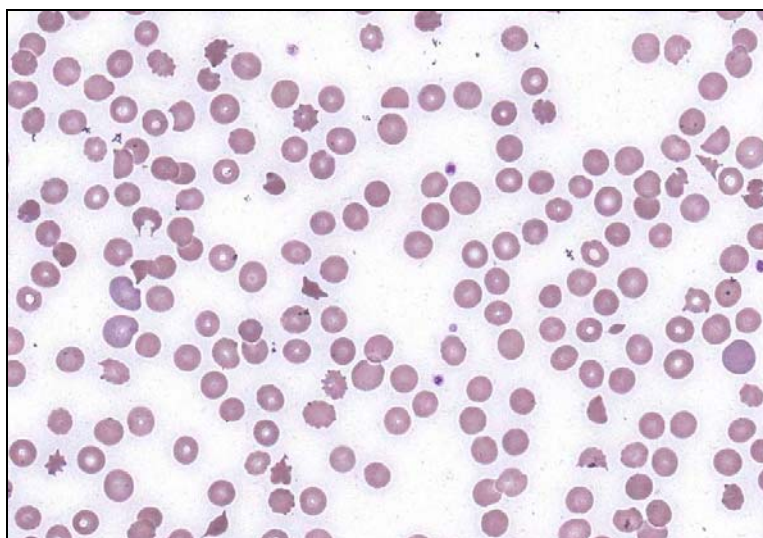
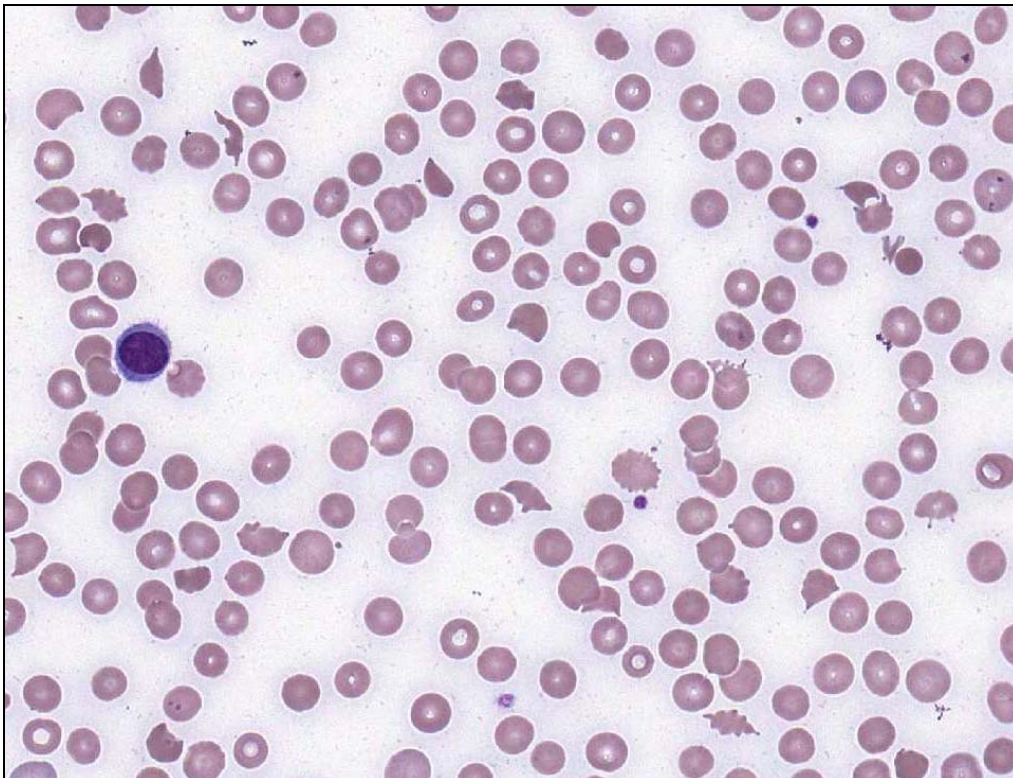




**INTERIM REPORT: MORPHOLOGY PROGRAM  
CASE STUDY MO9-10c DIAGNOSIS:  
Microangiopathic haemolytic anaemia secondary to brown snake bite.**

Illustrated below are photographs taken from Slide MO9-10c to demonstrate the morphological features in case study 3.



Discussion and other diagnostic interpretations that have been considered acceptable, by the Morphology Committee, will be listed in your final report